

## THROAT AND ESOPHAGUS

---

### Questions

- 357. Intermaxillary suture are sometimes raised forming a longitudinal midline ridge known as: (AFMC 2003)**
- Torus auditory
  - Torus mandibularis
  - Torus palatine
  - Torus maxillaris
- 358. Peritonsillar abscess is also known as: (Karnataka 98)**
- Retropharyngeal abscess
  - Tonsillar abscess
  - Quinsy
  - Thornwaldt's abscess
- 359. Third molar caries with extension of the lesion towards tonsillar fossa and shift of tonsil reveals which of the following complication? (UP 2002)**
- Parapharyngeal abscess
  - Retropharyngeal abscess
  - Tonsillar abscess
  - Dental abscess
- 360. Peritonsillar abscess can extend posteriorly into: (Delhi 2000)**
- Anterior triangle of neck
  - Parapharyngeal space
  - Posterior triangle on neck
  - Submaxillary space
- 361. Swelling between tonsillar area and superior constrictor muscle is know as: (AI 1991)**
- Quinsy
  - Dental abscess
  - Parapharyngeal abscess
  - Retropharyngeal abscess
- 362. The most common malignancy of the oropharynx: (MP 2006)**
- Tonsil
  - Soft palate
  - Tongue base
  - Valleculae

- 363. Killian's dehiscence is seen in (JIPMER 1999)**
- Oropharynx
  - Nasopharynx
  - Cricopharynx
  - Vocal cords
- 364. Odynophagia is (MH PGM CET 2000)**
- Pain during swallowing
  - Difficulty in swallowing
  - Bad odour from mouth
  - Psychiatric disease
- 365. Openings of the tube of bronchoscope are known as: (CMC 2002)**
- Holes
  - Apertures
  - Vents
  - Any of the above
- 366. Indications for tracheostomy are all EXCEPT:**
- Acute epiglottitis
  - Maxillofacial trauma
  - Laryngeal malignancy
  - Extensive consolidation of lung
- 367. Most common complication of Tracheostomy is: (JIPMER 2000)**
- Stenosis
  - Infection
  - Pneumonia
  - Respiratory failure
- 368. Collar stud abscess is seen in: (Orissa 2004)**
- Pyogenic cervical abscess
  - Peritonsillar abscess
  - Retropharyngeal abscess
  - TB lymphadenitis
- 369. A tracheostomised patient, with portex tracheostomy tube, in the ward, developed sudden complete blockage of the tube. Which of the following is best next step in the management? (AIIMS May 2004)**
- Immediate removal of the tracheostomy tube
  - Suction of tube with sodium bicarbonate
  - Suction of tube with saline
  - Jet ventilation

172 ENT

---

- 370. After a long-standing tracheostomy patient developed almost complete stenosis of trachea, treatment is: (AIIMS 2001)**
- Tracheal dilation
  - Laser with stent
  - Surgery
  - Removal of stenosed part with anastomosis
- 371. Not true regarding pterygopalatine fossa: (Orissa 2005)**
- Inferomedial to the foramen rotundum lies the Vidian (Pterygoid) canal, which connects the foramen lacerum to the pterygopalatine fossa.
  - Medially, the pterygopalatine fossa communicates through the pterygomaxillary fissure with the infratemporal fossa
  - It communicates with the middle cranial cavity through the foramen rotundum and pterygoid canal.
  - It contains the sphenopalatine ganglion and the third segment of the maxillary artery.
- 372. White oral lesions are seen in EXCEPT: (Kar 2002)**
- Leukoplakia
  - Keratosis
  - Addison's disease
  - Candidiasis
- 373. All of the following cause a grey-white membrane in the throat EXCEPT (SGPGI 2005)**
- Streptococcal tonsillitis
  - Diphtheria
  - Ludwig's angina
  - Adenoviral pharyngitis
- 374. True statement about faucial diphtheria is: (Delhi 2001)**
- Pearly white membrane
  - Bleeding occurs if the membrane is tried to remove
  - Bleeds when membrane is removed
  - Membrane can be removed easily
- 375. Collar stud abscess is seen in: (Orissa 2004)**
- Pyogenic cervical abscess
  - Peritonsillar abscess
  - Retropharyngeal abscess
  - TB lymphadenitis
- 376. Steeple sign is seen in: (SGPGI 2005)**
- Croup
  - Acute epiglottitis
  - Laryngomalacia
  - Quinsy

- 377. The antibiotic of choice in acute epiglottitis pending culture sensitivity report is: (Kar 2001)**
- Erythromycin
  - Rolitetracline
  - Doxycycline
  - Ampicillin
- 378. Which of the following statement is true for Ludwig's angina? (Delhi 2000)**
- It is an ischemic, painful condition of Pectoralis minor muscle
  - It is diffuse cellulitis affecting the floor of the mouth
  - Glycerin nitrate, local application is quite helpful
  - None of the above
- 379. Submandibular space infection is known as: (Manipal 2002)**
- Ludwig's angina
  - Vincent's angina
  - Parapharyngeal abscess
  - None
- 380. Which of the following structures are preserved in radical neck dissection? (Kar 2002)**
- Vagus nerve
  - Accessory Nerve
  - Internal jugular vein
  - Sternocleidomastoid muscle
- 381. Palatal myoclonus is seen in: (SGPGI 2005)**
- Epilepsy
  - Multiple sclerosis
  - Cerebellar infarction
  - Guillain Barre syndrome
- 382. What is the correct sequence of the following while resuscitating an infant with Foreign Body Airway Obstruction? (UPSC 2004)**
- Chest thrust
  - Tongue-jaw lift
  - Back blows
- Select the correct sequence form the codes given below:  
Codes:
- 1,3,2
  - 3,2,1
  - 3,1,2
  - 2,1,3

174 ENT

---

- 383. A patient presented with a 3.5 cms size lymph node enlargement, which was hard and presented in submandibular region. Examination of the head and neck did not yield any lesion. The next investigation to be done: (CMC 2005)**
- CXR
  - Triple endoscopy
  - Supravital staining of oral mucosa
  - Laryngoscopy
- 384. Most common tumor to produce metastasis to cervical lymph nodes: (AIIMS MAY 2002)**
- Glottic Carcinoma
  - Nasopharyngeal carcinoma
  - Carcinoma Base of tongue
  - Carcinoma lip
- 385. Best diagnostic modality for Nasopharyngeal angiofibroma is: (AIIMS 1997)**
- Angiography
  - Biopsy
  - CECT
  - MRI
- 386. Investigation of choice for Nasopharyngeal angiofibroma is: (MP 2002)**
- MRI
  - CECT
  - Helical CT
  - Angiography
- 387. Causes of posterior soft tissue nasopharyngeal mass include all EXCEPT: (AMU 1996)**
- Plasmacytoma
  - Choanal atresia
  - Thornwaldt's Cyst
  - Aneurysm of the carotid artery
  - Chordoma
- 388. All muscles of Palate are supplied by cranial accessory nerve except:**
- Tensor palati
  - Palatoglossus
  - Palatopharyngeus
  - None

**389. All muscles of Pharynx are supplied by cranial accessory nerve except:**

- a. Thyropharyngeus
- b. Inferior constrictor
- c. Stylopharyngeus
- d. Superior constrictor

**390. All muscles of Tongue are supplied by hypoglossal nerve EXCEPT:**

- a. Myoglossus
- b. Palatoglossus
- c. Genioglossus
- d. Hyoglossus

**391. Cranial accessory nerve supplies: (Orissa 99)**

- a. Palate
- b. Pharynx
- c. Palatoglossus
- d. All

**392. Mandibular nerve supplies: (PGI 89)**

- a. Tensor palati
- b. Tensor tympani
- c. Both
- d. None

**393. Most frequent site of branchial cyst is at: (MH-SS-CET 2005)**

- a. Upper third of posterior border of sternocleidomastoid
- b. Lower third of anterior border of sternocleidomastoid
- c. Upper third of anteromedial border of sternocleidomastoid
- d. Supraclavicular fossa

**394. The main differential diagnosis is second branchial cleft cyst include all EXCEPT:**

- a. Thyroglossal duct cyst
- b. Cystic hygroma
- c. Laryngocele
- d. Ranula

**395. Which of the following is not the site for PARAGANGLIOMA? (AIIMS Nov 2003)**

- a. Carotid bifurcation
- b. Jugular foramen
- c. Promontory in middle ear
- d. Geniculate ganglion

- 396. Bano Begum presented with bleeding from ear, pain, tinnitus and increasing deafness. Examination revealed red swelling/mass behind the intact tympanic membrane that blanches on pressure with pneumatic speculum. Treatments for her include all EXCEPT: (AIIMS 2001)**
- Preoperative embolisation
  - Radiotherapy
  - Surgery
  - Interferons
- 397. Which of the following is the most beneficial technique of using chemotherapy with a course of radiotherapy in head and neck malignancies? (AIIMS NOV 2004)**
- Neo adjuvant chemotherapy
  - Adjuvant chemotherapy
  - Concurrent chemotherapy
  - Alternating chemotherapy and radiotherapy
- 398. Which implant is used in Nasopharyngeal carcinoma: (Kerala 2005)**
- Caesium
  - I-131
  - Gold
  - Iridium
- 399. A male aged 60 years has foul breath, he regurgitates food that is eaten 3 days ago. Likely diagnosis is: (AIPGE 2001)**
- Zenker's diverticulum
  - Meckel's diverticulum
  - Scleroderma
  - Achalasia cardia
- 400. Main problem associated with carotid body tumor operation is: (Maharashtra 2000)**
- The tumor blends with bifurcation of carotid artery
  - The tumor blends with jugular vein
  - Recurrence
  - Vaso vagal Shock
- 401. True about Carotid body tumor is all EXCEPT: (AIIMS Nov 2004)**
- It is highly vascular mass
  - True cut biopsy is investigation of choice
  - Operative intervention is best avoided in elderly patients.
  - Radiotherapy has no effect

- 402. Investigation of choice for carotid body tumor? (AFMC 2004)**
- Angiography
  - USG with colour Doppler
  - CECT
  - MRI
- 403. A 40 year old patient is suffering from carotid body tumor. Which of the following is the best choice of treatment for him? (AIIMS 2004 may)**
- Excision of tumor
  - Radiotherapy
  - Chemotherapy
  - Carotid artery ligation both proximal and distal to the tumor
- 404. Lower esophageal sphincter: (AIIMS 2005 may)**
- Has no tonic activity
  - Has a tone which is provided by the sympathetic system
  - Relaxes on increasing abdominal pressure
  - Relaxes ahead of the peristaltic wave
- 405. A young patient presents with history of dysphagia more to liquids than solids. The first investigation you will do is: (AIIMS may 2003)**
- Barium swallow
  - Esophagoscopy
  - Laryngoscopy
  - CT chest
- 406. Barium study in Trendelenburg position is done for the diagnosis of: (Kerala 2003)**
- Upper GIT disorders
  - Hiatal disorders
  - Esophageal disorder
  - Crohn's disease
- 407. On a chest radiograph, a double shadow behind the heart, signs of aspiration pneumonia and absence of air in stomach is suggestive of: (KAR 2003)**
- Aneurysm of thoracic aorta
  - Achalasia
  - Carcinoma esophagus
  - Peptic ulcer (stomach)
- 408. "Rat-tail" appearance on barium swallow examination is seen in: (Maharashtra 2002)**
- Achalasia cardia
  - Carcinoma esophagus
  - Hiatus hernia
  - Diffuse esophageal spasm

**409. "Cobble stone" esophagus is feature of: (Orissa 94)**

- a. Candidial oesophagitis
- b. Cytomegalovirus oesophagitis
- c. Herpes oesophagitis
- d. Hiatus hernia

**410. "Rat tail Appearance" in barium swallow is a feature of: (KAR 2005)**

- a. Carcinoma of Esophagus
- b. Achalasia Cardia
- c. Barret's esophagus
- d. Chronic Reflux oesophagitis

**411. 'Cork-screw' esophagus is seen in: (AI 2002; KAR 2001)**

- a. Vigorous achalasia cardia
- b. Scleroderma
- c. Diffuse esophageal spasm
- d. Carcinoma esophagus

**412. Dysphagia lusoria due to: (AIIMS Nov 2003; Manipal 2002)**

- a. Esophageal diverticulum
- b. Aneurysm of aorta
- c. Esophageal web
- d. Compression of esophagus by aberrant blood vessel

**413. Dysphagia lusoria is commonly due to: (Manipal 2002)**

- a. Abnormal origin of left subclavian artery
- b. Abnormal origin of right subclavian artery
- c. Compression by aortic arch
- d. Obstruction by foreign body

**414. Corkscrew esophagus is seen in which of the following conditions? (AIPGE 2002)**

- a. Carcinoma esophagus
- b. Scleroderma
- c. Achalasia cardia
- d. Diffuse esophageal spasm

**415. Treatment for achalasia associated with high rate of recurrence: (AIPGE 2002)**

- a. Pneumatic dilatation
- b. Laparoscopic myotomy
- c. Open surgical myotomy
- d. Botulinum toxin

- 416. Barrett's oesophagus is: (AIPGE 2002)**
- Lower oesophagus lined by columnar epithelium
  - Upper oesophagus lined by columnar epithelium
  - Lower esophagus lined by ciliated epithelium
  - Lower esophagus lined by pseudostratified epithelium
- 417. Adenocarcinoma of esophagus develops in: (AIPGE 2002)**
- Barrett's esophagus
  - Long standing achalasia
  - Corrosive structure
  - Alcohol abuse
- 418. Most common site for squamous cell Carcinoma esophagus is: (AIPGE 2001)**
- Upper third
  - Middle third
  - Lower third
  - Gastro esophageal junction
- 419. Dysphagia lusoria is due to: (NOV. 2003 AIIMS)**
- Oesophageal diverticulum
  - Aneurysm of aorta
  - Oesophageal web
  - Compression by aberrant blood vessels
- 420. A 30 years old male, presents with symptoms of regurgitation of foul smelling food, and dysphagia. He is diagnosed to have cricopharyngeal diverticulum. Management of choice is: (AIIMS 2001)**
- Excision of the diverticula
  - Cricopharyngeal myotomy alone
  - Myotomy with excision of the sac
  - Marsupialization of the sac
- 421. Bhanwarilal presents with feature of foul smelling food regurgitation, dysphagia and pain. He was diagnosed to have cricopharyngeal diverticulum. Treatment of choice will be: (AIIMS 2000)**
- LASER vaporization
  - Excision of the diverticulum with cricopharyngomyotomy
  - Excision of the diverticulum
  - Marsupialisation of the diverticulum

- 422. Best substitute for esophagus after esophagectomy is: (MP 99; Ai 96)**
- Stomach
  - Jejunum
  - Right colon
  - Left colon
- 423. A young patients with dysphagia move for liquids than solids. He regurgitates food often at night. Radiography shows a rat-tailed appearance. Likely diagnosis is: (AIIMS May 1996)**
- Achalasia cardia
  - CA oesophagus
  - Zenker's diverticulum
  - Diffuse esophageal spasm
- 424. A male aged 60 years has foul breath; He regurgitates food that is eaten 3 days ago a gurgling sound is often heard on swallowing: Likely diagnosis is: (AI 2001)**
- Zenkens diverticulum
  - Meckels diverticulum
  - Scleroderma
  - Achalasia cardia
- 425. All are true regarding Plummer Vinson syndrome, except: (AIIMS Dec 97)**
- Oesophageal web
  - Predisposes to malignancy
  - Koilonychia
  - Common in elderly males
- 426. The following are predisposing factors for Esophageal carcinoma except: (AI 1996)**
- Plummer-Vinson syndrome
  - Tylosis palmaris
  - Chronic Achalasia
  - Benzene therapy
- 427. Hyperkeratosis of palm and sole is seen in: (AIIMS Dec 97)**
- Carcinoma colon
  - Hepatoma
  - Adenocarcinoma lung
  - CA oesophagus

- 428. The adenocarcinoma of esophagus-developed in: (AI 2002)**
- Barrett's esophagus
  - Long standing achalasia
  - Corrosive structure
  - Alcohol abuse
- 429. Adenocarcinoma of esophagus is commonly found in: (AI 1998)**
- Achalasia acardia
  - Barrett's oesophagus
  - Plummer Vinson syndrome
  - Chronic smoking
- 430. Most common site for squamous cell carcinoma esophagus is: (AI 2001)**
- Upper third
  - Middle third
  - Lower third
  - Gastro-esophageal junction
- 431. Which neo-adjuvant chemotherapy is used in Esophageal carcinoma: (AI 1996)**
- Cisplatin
  - Cyclophosphamide
  - Doxorubicin
  - Methotrexate
- 432. The commonest side effect of cisplatin in a patient using it for esophageal carcinoma is: (AIIMS May 01)**
- Acute tubular necrosis
  - Thrombocytopenia
  - Hepatic failure
  - Cardiomyopathy
- 433. Constrictions normally present in esophagus are all EXCEPT: (MH-PGM-CET-2000):**
- 10 cm from the incisor teeth
  - 15 cm from the incisor teeth
  - 25 cm from the incisor teeth
  - 40 cm from the incisor teeth
- 434. Which of the following play vital role in preventing gastro oesophagus reflux? (PGI 2001)**
- Sphincteric action of lower esophageal muscle fibers or fibers of right cura.
  - Mucosal flap produced by muscularis mucosa of the stomach.
  - Difference between intrathoracic and intraabdominal pressure.
  - Acute gastroesophageal angle.

182 ENT

---

**435. The most common complication seen in hiatus hernia is: (AI 2005)**

- a. Oesophagitis
- b. Aspiration pneumonitis
- c. Volvulus
- d. Oesophageal stricture

**436. The hypopharynx includes all the following EXCEPT: (JIPMER 2003)**

- a. Pyriform fossa
- b. Epiglottis
- c. Post cricoid region
- d. Valeculae

# THROAT AND ESOPHAGUS

---

## Answers

357. **Ans: (c) (Torus palatine)**

**Torus palatine**

Intermaxillary suture are sometimes raised forming a longitudinal midline ridge called torus palatine.

**Torus auditory**

The posteroinferior wall of external meatus occasionally presents a smooth to roughened longitudinal elevation, known as auditory torus.

**Torus mandibularis**

Above Mylohyoid line, the bone medial to roots of molar teeth is sometime developed into a rounded ridge called torus mandibularis.

**Torus maxillaris**

It is occasionally present on the alveolar process spanning the palatal aspect of subcervical roots of upper molar teeth.

358. **Ans: (c) (Quinsy)**

(Ref. *Diseases of ENT by PL Dhingra – 2<sup>nd</sup> edition – 261*)

**Peritonsillar abscess (Quinsy)** is collection of pus between capsule of tonsils and superior constrictor muscle.

It is characterized by hot potato voice and odynophagia and halitosis. While draining it should be opened at the point of maximum bulge above upper pole of tonsil or just lateral to point of junction of anterior pillar, with a line drawn through the base of uvula.

Tonsils are removed 4-5 weeks following an attack of Quinsy.

**Retropharyngeal abscess**

- ◆ Acute (Pediatric)
- ◆ Chronic (Adult, LN tuberculosis)

Parapharyngeal abscess is **abscess of pharyngomaxillary or lateral pharyngeal spaces.**

359. **Ans: (a) (Parapharyngeal abscess)**

The parapharyngeal space is located lateral to the pharyngeal constrictor muscles. The fibrofatty plane adjacent to the nasopharyngeal wall constitutes the symmetrical parapharyngeal space. The posterior boundary of the parapharyngeal space is formed by the carotid sheath, which contains the carotid artery, jugular vein, cranial nerves (IX-XII), sympathetic plexus, and

lymphatic system. The styloid process with the origin of its three muscles (styloglossus, stylopharyngeus, and stylohyoid) lies posterolateral to the parapharyngeal space. The deep portion of the parotid gland forms the lateral border of the parapharyngeal space. The parapharyngeal space extends from the base of skull to the level of the hyoid bone and is triangular, with the base extending to the skull table. Hence, third molar caries with extension of the lesion towards tonsillar fossa and shift of tonsil is suggestive of parapharyngeal abscess.

**360. Ans: (b) (Parapharyngeal space)**

*(Ref. above Q for explanation)*

**Peritonsillar abscess (Quinsy)** is collection of pus between capsule of tonsils and superior constrictor muscle. Peritonsillar abscess can extend posteriorly into parapharyngeal space.

**361. Ans: (a) (Quinsy)**

*(Ref. Disease Of ENT By PL Dhingra 2<sup>nd</sup> ed.-261, 3<sup>rd</sup> ed. 318; ref. above Q. for explanation)*

Quinsy is collection of pus between capsule of tonsils and superior constrictor muscle.

- ◆ Retropharyngeal abscess is a complication of bacterial pharyngitis observed in children younger than 6 years. The patient presents with abrupt onset of high fevers, difficulty swallowing, refusal to feed, sore throat, hyperextension of the neck, and respiratory distress.
- ◆ Peritonsillar abscess is an infection in the potential space between the superior constrictor muscles and the tonsil. It is common in adolescents and preadolescents. The patient develops severe throat pain, trismus, and trouble swallowing or speaking.

**362. Ans: (a) (Tonsil)**

Carcinomas of the tonsil are the most common malignancies of the oropharynx. They may spread posterolateral to the internal jugular vein group of nodes and digastric nodes. Extension along mucosal surfaces to the glossopharyngeal sulcus and hypopharynx requires intravenous contrast to differentiate tumors from lingual tonsils. At times, differentiation of tonsillar carcinomas from tongue-base carcinomas may be impossible by CT or MR. Since mucosal changes are difficult to detect with these modalities, clinical information is essential for determining the exact site of origin. Lateral spread through the superior constrictor muscle to the space may cause lingual, hypoglossal, and inferior alveolar nerve deficits.

Pharyngeal wall carcinomas generally present late because of the lack of symptoms associated with tumors in this region. Deep posterior invasion to the anterior spinal ligament rarely occurs, despite the relatively large tumor size at presentation. Spread to the parapharyngeal space occurs more often. The most common route of lymph-node spread is to the retropharyngeal nodal group and to the highest internal jugular chain.

**363. Ans: (Cricopharynx)**

(Ref. Disease Of ENT By PL Dhingra 2<sup>nd</sup> ed.-235, 3<sup>rd</sup> ed.290)

Inferior constrictor muscle has two parts:

Thyropharyngeus (oblique fibers)

Cricopharyngeus (transverse fibers)

Between these two parts exists a potential gap, known as "Killian's dehiscence" (gateway of tears).

*Clinical significance:*

Perforation during esophagoscopy

Pharyngeal pouch

**364. Ans: (a) (Pain during swallowing)**

(Ref. Disease Of ENT By PL Dhingra 2<sup>nd</sup> ed.-332, 3<sup>rd</sup> ed.402, 444)

Odynophagia → painful deglutition.

Dysphagia → difficulty in deglutition.

Dysphagia lusoria → esophageal compression due to aberrant vessel, leading to dysphagia.

Globus hystericus → psychiatric condition characterized by dysphagia.

Halitosis is → bad odour from mouth.

**365. Ans: (c) (Vents)**

(Ref. Bronchology by Lukomsky – 40; Diseases of ENT by PL Dhingra 2<sup>nd</sup> ed. 484, 528)

**Bronchoscope** is similar to esophagoscope, but has openings at the distal part of the tube, called VENTS, which help in aeration of the side bronchi.

Size of bronchoscope will vary with age of the patient, with adult size being 9mm luminal diameter and 40cm length of tube. Vents are so placed that at least the upper few are above the level of carina to ventilate the rest of the lung when the bronchoscope is inserted into the major bronchus.

**Jackson's Dictum:** In the case of suspected or expected foreign body, it is safer to perform bronchoscopy rather than with holding it.

Advantage of flexible **fibre-optic bronchoscopy**;

- ◆ Provides magnification and better illumination.
- ◆ Permits examination of sub-segmental bronchi.
- ◆ Easy in patients with neck/jaw abnormalities

- ◆ Can be performed under topical anaesthesia
- ◆ Suction/biopsy channels are provided which helps to remove secretions, inspissated plugs of mucus or even small foreign bodies.
- ◆ It can be easily placed through endotracheal tube or tracheostomy opening. However, it has limited utility in children due to problem of ventilation.

**366. Ans: (d) (Extensive consolidation of lung)**

**Indications for tracheostomy**

A. Obstructive causes

B. Non-obstructive causes

**A. Obstructive causes**

1. Congenital

- Subglottic stenosis
- Laryngomalacia
- Glottic webs
- Hemangioma
- Large cyst
- Pierre Robin syndrome
- Cystic hygroma
- Lymphangioma
- Hemangioma of base of tongue

2. Inflammatory

- Acute laryngotracheobronchitis
- Acute epiglottitis
- Diphtherial laryngitis in children
- Laryngeal edema
- Extra-laryngeal Parapharyngeal abscess
- Retropharyngeal abscess

3. Traumatic

- Laryngeal trauma
- Inhalation of fumes
- Swallowing of corrosives
- Maxillofacial trauma
- Haematoma of the base of tongue
- Mandibular fracture
- Cervical haematoma

4. Neoplastic

- Respiratory recurrent papilloomatosis
- Adenoma
- Chondroma
- Laryngeal malignancy
- Pharyngeal malignancy

- Third malignancy
  - Esophageal malignancy
  - Mediastinal malignancy
5. Neurological
- Bilateral abductor paralysis
  - Thyroidectomy
  - Cardiac surgery
  - Allergic Angioneurotic edema
- B. Nonobstructive causes
- Assisted ventilation
  - Aspiration
  - Anaesthesia

**Atelectasis**

**367. Ans: (b) (Infection)**

**Complications of tracheostomy**

- I. Immediate
  - a. Apnea due to sudden decrease in CO<sub>2</sub>. Treated with carbogen.
  - b. Bleeding from veins or thyroid gland
  - c. Collapse of lung
  - d. Cardiac failure (excess adrenaline, rapid rise of pH and hypercalcemia)
  - e. Damage of surrounding structures (nerves, vessels, cartilage, esophagus)
  - f. Embolism (air), position of patient will prevent embolism
  - g. Emphysema (subcutaneous)
  - h. Fistula (TO fistula)
- II. Intermediate
  - a. Dislodgement of the tube
  - b. Blocked tube
  - c. Tracheitis
  - d. Emphysema
  - e. Bleeding
  - f. Tracheovenous fistula
  - g. Pneumothorax
- III. Late
  - a. Tracheocutaneous fistula leads to
    - i. Continuous secretions
    - ii. Skin irritation
    - iii. Disturbed phonation
    - iv. Frequent infection
    - v. Poor cosmesis
  - b. Tracheal stenosis (inflatable cuff, scar contracture, repeated incision, tracheal infection, organic disease of trachea)
  - c. Difficult decannulation

**368. Ans: (d) (TB lymphadenitis)**

Tubercular cervical adenopathy with caseation in nodes

**369. Ans: (a) (Immediate removal of the tracheostomy tube)**

(Ref: Logan Turner's 10<sup>th</sup> Ed.-196)

In a tracheostomised patient, with portex tracheostomy tube who has developed sudden complete blockage of the tube, immediate removal of it with insertion of new tube is warranted.

**370. Ans: (d) (Removal of stenosed part with anastomosis)**

(Refer above Q for explanation)

Tracheal stenosis developing in a patient with long-standing tracheostomy should be treated with removal of stenosed part of trachea and anastomosis.

**371. Ans: (b) (Medially, the pterygopalatine fossa communicates through the pterygomaxillary fissure with the infratemporal fossa)**

**PTERYGOPALATINE FOSSA**

The pterygopalatine fossa is situated between the posterior wall of the maxillary antrum and the pterygoid plates. Its medial margin is the perpendicular plate of the palatine bone; this is perforated by the sphenopalatine foramen, which connects the fossa with the nasal cavity. Laterally, the pterygopalatine fossa communicates through the pterygomaxillary fissure with the infratemporal fossa. The pterygopalatine fossa also communicates with the middle cranial cavity through the foramen rotundum and pterygoid canal, the orbit through the inferior orbital fissure, and the oral cavity through the pterygopalatine canal. The fossa contains the sphenopalatine ganglion and the third, or pterygopalatine, segment of the maxillary artery.

**372. Ans: (c) (Addison's disease)**

(Ref. Diseases of ENT by Bhargava 6<sup>th</sup> ed. 211)

White patch on the tongue or oral mucosa is seen in:

Leukoplakia (Premalignant)

Lichen planus (Premalignant)

Behcet's syndrome

Streptococcal infection

Diphtheria, Vincent's angina, Syphilis

Moniliasis (Oral thrush or Candidiasis)

Aphthous ulcers with slough at the base

Viral pharyngitis

Oral submucous fibrosis and erythroplakia are other premalignant oral lesions.

- 373. Ans: (c) (Ludwig's angina)** (*Refer above Q for explanation*)  
 Ludwig's angina, a cellulitis of the fascial spaces of the floor of the mouth and upper neck initiated by infected teeth, has a fatal outcome in as many as 10% of cases because of compromise of the upper airway, spread to the anterior mediastinum, or both. It does not cause membrane formation in throat.
- 374. Ans: (b) (Bleeding occurs if the membrane is tried to remove)**  
 (*Ref. PL Dhingra 3<sup>rd</sup> ed. 195*)  
 Faucial diphtheria  
 IP is 2-6 days  
 Children are more commonly affected.  
 Oropharynx is commonly involved and larynx, nose may also be involved. Greyish-white membrane forms over tonsils and spread to soft palate and posterior pharyngeal wall.  
 Bull neck can result due to nodal enlargement.  
 Patient is usually toxic.  
 Membrane formed is tenacious and bleeds on trial to remove.
- 375. Ans: (d) (TB lymphadenitis)**  
 Tubercular cervical adenopathy with caseation in nodes
- 376. Ans: (a) (Croup)** (*Ref. RRM Dahnert 5<sup>th</sup> ed. 377*)  
 Croup or Acute Laryngotracheobronchitis  
 Croup is most common viral in etiology with parainfluenza viruses often being implicated. It mainly involves the subglottis and trachea with swelling causing obstruction at the level of the cricoid cartilage. Parainfluenza or RSV causes Croup or acute laryngotracheobronchitis or acute viral spasmodic laryngitis, with peak incidence between 2-3 years of age. Hoarse cry and brassy cough are its characteristic features. Steeple sign is characteristic radiographic feature of croup characterized by subglottic 'inverted V' i.e. symmetrical funnel-shaped narrowing 1-1.5 cm below lower margins of pyriform sinuses on AP radiograph (loss of normal 'shouldering' of air column caused by mucosal edema and external restriction of cricoid), accentuated on expiration, paradoxical inspiratory collapse, less pronounced during expiration.  
 Thumb sign is seen in acute epiglottitis on lateral neck radiograph. Acute laryngitis can be caused by a variety of bacterial and viral agents that may cause edema, ulceration, and pseudomembrane formation.
- 377. Ans: (a) (Erythromycin)**  
 Acute epiglottitis occurs mainly in children and can rapidly progress to airway obstruction. The most common organism implicated is Hemophilus influenzae type B, and response to macrolides is the rule.

**378. Ans: (b) (It is diffuse cellulitis affecting the floor of the mouth)***(Ref. Dhingra 3<sup>rd</sup> ed. 277)***Ludwig's angina**

It is the infection of submandibular space, which lies between mucous membrane of the floor of mouth and tongue on one side and superficial layer of deep cervical fascia extending between the hyoid bone and mandible on the other.

It is divided into two compartments by the Mylohyoid muscle, but they continue posteriorly.

a. Sublingual (above the Mylohyoid)

b. Submaxillary and submental compartment (below the Mylohyoid)

**Causative organism:**

Aerobes and anaerobe.

Alpha hemolytic streptococci

Bacteroids are common.

H. influenza rarely.

**Etiology:**

Dental infections

Submandibular sialadenitis

Injury of oral mucosa

Mandibular fractures

**Treatment:** Antibiotics and I and D.

**379. Ans: (a) (Ludwig's angina)**

It is the infection of submandibular space, which lies between mucous membrane of the floor of mouth and tongue on one side and superficial layer of deep cervical fascia extending between the hyoid bone and mandible on the other.

**380. Ans: (a) (Vagus nerve)***(Ref. Bhargava 6<sup>th</sup> ed. 211)***Radical neck dissection**

Structures excised	Structures preserved
1. Fascia and fatty tissue	ICA
2. Lymph nodes	ECA (may be sacrificed)
3. Sternomastoid	Brachial plexus
4. IJV	Hypoglossal nerve
5. EJV	Vagus nerve
6. Accessory nerve	Phrenic nerve
7. Submandibular gland	Facial nerve (cervical and marginal mandibular branches)
8. Tail of Parotid	Sympathetic trunk

**Commonest incisions:**

1. Crile's incision (modified Y incision)
2. Macfee's incision (double horizontal incision) in irradiated neck.

**381. Ans: (b) (Multiple sclerosis)**

Palatal myoclonus can occur in multiple sclerosis.

**382. Ans: (c) (3,1,2)**

Aspiration of foreign body is common in children aged 1-2 years. Usually, foreign bodies are food such as nuts, hot dogs, popcorn, and hard candy that is inhaled. A history of coughing and choking that precedes development of respiratory symptoms may be present.

Lack of ventilation is an acute or subacute sign of bronchial foreign body. After weeks or months, infection sets in beyond the foreign body, and the appearance is one of collapse and pneumonia. Recurrent fever and unchanging collapse in one or more adjacent basal segments should immediately suggest a retained bronchial foreign body.

The correct sequence of the following while resuscitating an infant with Foreign Body Airway Obstruction is back blows (Helmich maneuver) → tongue-jaw lift → chest thrust.

**383. Ans: (b) (Triple endoscopy)**

The patient in question has developed cervical lymphadenopathy and there is no obvious cause in head and neck, hence as bronchi, larynx or upper gastrointestinal system can be the source of occult primary, search for primary at these site with the help of triple endoscopy (laryngoscopy + bronchoscopy + upper GI scopy) will be the most fruitful examination.

**384. Ans: (b) (Nasopharyngeal carcinoma)**

(Ref. Logan Turner, 10<sup>th</sup> Ed.203)

Primary sites producing metastasis to cervical lymph nodes are in decreasing order of frequency:

1. Nasopharynx
2. Tonsil
3. Base of tongue
4. Thyroid gland
5. Supraglottic larynx
6. Floor of the mouth
7. Palate
8. Pyriform fossa
9. Bronchus
10. Esophagus
11. Breast

## 12. Stomach

Glottic carcinoma never metastasizes to lymph nodes and carcinoma lip metastasizes rarely and very late.

**385. Ans: (c) (CECT)**

(Ref. Grainger's Diagnostic Radiology, 4th ed., 2556, 2618)

**Juvenile nasopharyngeal angiofibroma**

It is a tumor of adolescent boys.

It typically presents as nasal mass with recurrent epistaxis. Life-threatening hemorrhage has occurred from biopsy and therefore radiological features are relied upon to establish diagnosis.

It is the most common benign nasopharyngeal tumor, which can grow enormously and invade local vital structures.

**Age:** Teenagers (peak 15 yrs); almost exclusively in males.

It is highly vascular mass supplied primarily by internal maxillary artery.

**Extensions:**

Posterolateral wall of nasal cavity; via pterygopalatine fossa into retroantral region, orbit; Middle cranial fossa and laterally into infratemporal fossa

**Radiological features:**

Widening of pterygopalatine fossa (90%) with anterior bowing of posterior antral wall, invasion of sphenoid sinus through floor of sinus (66%), Widening of inferior orbital fissure (orbital spread) and Superior orbital fissure (middle cranial fossa spread).

Angiography is not required to establish the diagnosis, but has valuable role in preoperative therapeutic embolization to reduce blood loss.

CECT is investigation of choice for diagnosis and evaluation of the mass.

It shows bright intense contrast enhancement immediately and long erosion and invasion can be best visualized.

A *reliable imaging sign* is erosion of medial pterygoid plate and enlargement of sphenopalatine foramen.

HRCT allows accurate diagnosis since these tumors start in pterygopalatine fissure, which enlarge before they extend. MRI is reliable for defining tumor extension, which may involve the posterior nasopharynx, middle cranial fossa and infratemporal fossa.

MRI shows intermediate signal intensity on T1W1 with discrete punctate areas on hypointensity.

Biopsy is contraindicated.

Combination of CT and CEMRI may be required for accurate diagnosis imaging which reveals an enhancing mass, which arises from the posterolateral nasal wall adjacent to sphenopalatine foramen.

**386. Ans: (b) (CECT)**

(Refer above Q for explanation)

**387. Ans: (b) (Choanal atresia)**

Choanal atresia does not produce any mass lesion.

Thornwaldt's Cyst

In 3% of individuals, a pit or outpouching exists high in the posterior midline nasopharynx, which is lined by pharyngeal epithelium. Although a persistent tract of Rathke's pouch may be present at birth, it usually causes no problem unless the opening of the pharyngeal bursa becomes closed by inflammation that results in cyst formation. Males and females are affected equally, usually in the second and third decades of life. The presenting complaint is usually persistent postnasal discharge with unpleasant taste or halitosis.

Hypertrophied and normal lymphoid tissue is commonly seen in the nasopharynx of individuals up to 35 years old.

**MALIGNANT TUMORS** related to posterior nasopharyngeal wall:

Squamous-cell carcinoma

- ◆ Adenocarcinoma
- ◆ Adenoid cystic carcinoma
- ◆ Lymphoma
- ◆ Chordoma
- ◆ Rhabdomyosarcoma
- ◆ Fibrosarcoma
- ◆ Chondrosarcoma
- ◆ Plasmacytoma
- ◆ Hemangiopericytoma
- ◆ Chemodectoma
- ◆ Malignant melanoma
- ◆ Malignant tumors with secondary nasopharyngeal involvement arising from the Nasal cavity, Sinuses, Parotid gland and **Metastatic lymph nodes.**

**388. Ans: (a) (Tensor palati)**

- ◆ All muscles of Palate are supplied by cranial accessory nerve except Tensor palati (Mandibular Nerve)
- ◆ All muscles of Face are supplied by VII cranial nerve except LPS (Occulomotor)
- ◆ Cranial accessory nerve supplies Palate Pharynx Palatoglossus
- ◆ Mandibular nerve supplies Tenor palati and tympani

**389. Ans: (c) (Stylopharyngeus)**

- ◆ All muscles of Pharynx are supplied by cranial accessory nerve except Stylopharyngeus (IX nerve)

**390. Ans: (b) (Palatoglossus)**

(Refer above Q for explanation)

- ◆ All muscles of Tongue are supplied by hypoglossal nerve except Palatoglossus (Cranial accessory nerve)

**391. Ans: (d) (All)**

(Refer above Q for explanation)

**392. Ans: (a), (b)**

Beyond the ganglion, the nerve trifurcates into the ophthalmic, maxillary and mandibular divisions. The ophthalmic nerve goes through the inferolateral aspect of the cavernous sinus before entering the orbit through the superior orbital fissure. The maxillary and mandibular branches exit through foramen rotundum, and foramen ovale, respectively. The nerve is primarily involved with sensory innervation to the face, eye, and mucosa of nasal and oral cavities, including the teeth. The mandibular nerve also has motor supply to the muscles of mastication (temporalis, masseter, medial, and lateral pterygoids), tensor tympani, tensor veli palatini, anterior belly of digastric, and mylohyoid.

**393. Ans: (c) (Upper third of anteromedial border of sternocleidomastoid)**

(Ref. Grainger Diagnostic Radiology 4<sup>th</sup> 2619)

**Branchial Cyst**

Branchial cysts are embryological cysts derived from the cervical pouch.

First branchial cleft cyst results in cyst near external auditory canal or parotid gland.

Second branchial cleft cyst is most common (95% of all branchial cleft anomalies) and present as mass in anterior triangle of neck close to the angle of mandible. Type II second branchial cysts are most common among the 4 types of second branchial cleft cysts and are classically located at anteromedial border of sternocleidomastoid muscle, lateral to carotid space and at posterior margin of submandibular gland in close proximity to internal and external carotid artery.

Third branchial cleft cyst present as posterior cervical space mass

**394. Ans: (d) (Ranula)**

The main differential diagnosis is second branchial cleft cyst is (thyroid remnant cyst) TRC. A true TRC passes posterior to carotid bifurcation and terminates in the pyriform sinuses, while the second branchial cysts passes in between the internal and the external carotid arteries and ends in the superior tonsillar pillar. About 50% of TRC extend into the superior mediastinum where as mediastinal extension with branchial cleft anomalies do not occur. If a mass is located in the area of inferior pole of the thyroid gland, a thymic origin of the lesion should be considered. The other differential diagnosis of TRC is thyroglossal duct cyst, Lymphatic malformation, Cystic neuroblastoma, lymphadenopathy, external laryngocele and vallecular cyst.

**395. Ans: (d) (Geniculate ganglion)**

(Ref. Osborn's *Neuroradiology*, 450 and 507; Grainger's *Diagnostic Radiology*, 4th ed., 368, 2341, 2547, 2561)

**Parasympathetic paragangliomas (Chemodectomas, Glomus tumor)**

These arise from the paraganglia that exist in various locations in the body, the most common head and neck sites of these tumors being the carotid body/bifurcation (carotid body tumor/chemodectoma/potato tumor), jugular foramen (Glomus jugulare) and middle ear (Glomus tympanicum) and Vagus nerve (Glomus vagale).

- ◆ Glomus jugulare is situated in the jugular bulb adventitia immediately below the middle ear.
- ◆ Glomus tympanicum are the paragangliomas that are localized to cochlear promontory in the middle ear cavity.
- ◆ Glomus jugulotympanicum tumors extend from jugular foramen into the middle ear cavity.
- ◆ The "salt and pepper" appearance is typical for paraganglioma on MR scan study.
- ◆ Pheochromocytoma of adrenal medulla is the most common paraganglioma.
- ◆ Other extraadrenal sites are spine, mediastinum and paraaortic.

**396. Ans: (d) (Interferons)**

(Ref. LB 21st-678; Dhingra 2nd 144)

Red swelling/mass behind the intact tympanic membrane that blanches on pressure with pneumatic speculum with clinical complaints of bleeding from ear, pain, tinnitus and increasing deafness in a female patient is likely to be glomus tympanicum.

**397. Ans: (a) (Neo adjuvant chemotherapy)**

(Walter and Miller's textbook of radiotherapy 5<sup>th</sup> ed. 313)

In general for early disease radical RT or surgery may offer comparable local control. For advanced disease, the prospects to cure by local RT diminish and radical surgery is preferred.

Chemotherapy is not curative but useful palliator can sometimes be achieved in advanced disease now controlled by surgery or RT.

**398. Ans: (d) (Iridium)**

Tongue (T1 and T2) → Iridium implant (65-70 Gy)

Tongue (T3 and T4) → inoperable → 60 Gy in 25 daily fractions over 5 weeks (4-6 MV photons)

Buccal cheek → 40 Gy in 20 daily fractions for 4 weeks followed by iridium implant

Low grade NHL → 35 Gy in 20 daily fractions over 4 weeks

High grade NHL → 40-45 Gy in 20 daily fractions over 4 weeks

Nasopharyngeal Ca → 40 Gy in 20 daily fractions over 4 weeks (iridium)

Pinna → 50 Gy in 10 daily fractions over 2 weeks

Salivary gland tumors → 60 GY in 25 daily fractions over 5 weeks

Megavoltage (4-6 MV photons or high energy electrons)

**Ca Larynx → 60 GY in 25 daily fractions over 5 weeks**

Postcricoid malignancy → 60 GY in 25 daily fractions over 5 weeks

**Esophagus → 52.5 GY in 20 daily fractions over 4 weeks (9-10 MV photons)**

**399. Ans: (a) (Zenker's diverticulum)**

**Zenker's diverticulum** is pulsion diverticulum, where pharyngeal mucosa herniates through the Killian's dehiscence (a weak area between two parts of inferior Constrictor)

Age: This condition is usually seen after 60 years of age (elderly)

Symptoms:

Dysphagia: As mouth of the sac is wider than the opening of esophagus, food preferentially enters the sac. When the pouch gets filled with food, it presses on the esophagus and produces dysphagia.

Gurgling Sound is produced during swallowing.

Cough and Aspiration pneumonia: Food eaten over the last few days may regurgitate as it collects in pouch causing cough and aspiration pneumonia.

Malnutrition: Patient is often malnourished due to dysphagia.

**400. Ans: (a) (The tumor blends with bifurcation of carotid artery)**

(Ref. Bailey and Love-23<sup>rd</sup> ed.-955, 24<sup>th</sup> 774)

**Chemodectoma / Carotid body tumor / Potato tumor**

Most frequent paraganglioma of head and neck

Derived from third branchial arch and neural crest cells.

Rare neurogenic tumor presenting in 5<sup>th</sup> decade, arising from chemoreceptor cells on medial aspect of carotid bulb and, at this point tumor is adherent to carotid wall. This makes its surgical excision potentially serious.

Most common age =30-40 yrs

M:F=1:3

Bilateral in 5%

Multicentric in 3% (associated with other paragangliomas)

Located within the adventitia of carotid bifurcation

Usually asymptomatic

But presents as slowly enlarging painless lump in neck at the level of carotid bifurcation i.e. a pulsatile neck mass below the angle of mandible The mass is firm, rubbery, pulsatile and mobile from side to side only.

Malignant transformation in 6%

May be associated with pheochromocytomas

Radiological features:

CT:

It is highly vascular mass and CECT neck is ideal modality as an investigation to diagnose it.

Oval mass involving the carotid space splaying the internal and external carotid arteries

Focal hypodense area may be seen due to necrosis with marked enhancement (may be minimal or absent if thrombosis had occurred)

Calcification is rare

May extend into Para pharyngeal space in 8% cases

MRI:

Characteristic 'Salt & pepper' appearance with areas of hypointensity and hyperintensity on enhanced T1W1 due to multiple vessels within

The mass and enhancing stroma

Tumor is predominantly isointense on T1W1 & T2W1 with patchy areas of T2-hyperintensity

Marked enhancement (variable if thrombosis has occurred)

ANGIOGRAPHY:

Spaying of internal and external carotid arteries

Nutrient vessels seen in arterial phase

Marked vascularity with dense tumor blush in the capillary phase

**401. Ans: (b) (True cut biopsy is investigation of choice)**

**Carotid body tumors** are one of many of a family of paragangliomas that involve the head and neck. These are usually benign, well-

encapsulated masses located at the carotid bifurcation. These tumors are hypervascular and may be bilateral, frequently producing an audible bruit. Some produce catecholamines that can produce sudden changes of blood pressure postoperatively or after manipulation of the carotid bifurcation vessels. Carotid body tumors arise from the carotid body at the level of the carotid bifurcation. Many extend medially far enough to produce a bulge in the oropharyngeal wall. On an angiogram, they appear as vascular masses producing a characteristic splaying of the internal and external branches of the carotid artery.

**402. Ans: (c) (CECT)**

Carotid body tumors arise from the carotid body at the level of the carotid bifurcation. On CECT, they appear as well-defined highly vascular masses producing a characteristic splaying of the internal and external branches of the carotid artery. Many extend medially far enough to produce a bulge in the oropharyngeal wall

**403. Ans: (a) (Excision of tumor)**

Management of carotid body tumor:  
Resection is for cure and radiation for control.  
But, operative intervention is best avoided in elderly patients.  
Some times mass may not be separable from the vessels and resection will be necessary with graft for continuity in carotid system.

Radiotherapy has no good effect.  
The given patient is 40 years old (not elderly); hence, Excision or resection of tumor will be best treatment for him.

**404. Ans: (d) (Relaxes ahead of the peristaltic wave)**

The presence of a physiologic sphincter at the lower end of the esophagus, called the LES, is currently accepted as the main choice for the antireflux barrier.

The presence of a physiologic sphincter characterized by a 2 to 4 cm high-pressure zone in the EGR has been acknowledged for several decades. This high-pressure zone has been called the lower esophageal sphincter, or LES, and is believed to be the main candidate for the antireflux barrier. Attempts to identify the LES anatomically have been largely unsuccessful, although asymmetric muscle thickening approximately the cardiac incisura has been shown recently.

This physiologic sphincter corresponds generally in location to the anatomic lower esophageal vestibule. In the resting state, the LES is a tonically contracted area that normally maintains a closing

pressure of 15 to 35 mmHg higher than the intragastric pressure. Within several seconds after swallowing, the *LES relaxes and remains relaxed until the peristaltic wave reaches the end of the esophagus.*

The two important physiologic functions of the LES are prevention of gastroesophageal reflux and relaxation with swallowing to permit movement of ingested material into the stomach.

**405. Ans: (a) Barium Swallow**

*(Ref. Grainger's Diagnostic Radiology, Vol II)*

Endoscopic USG only overcomes limitation of CT in assessing esophagus. Role of CT in esophageal disease is mainly confined to cancer staging. Despite widespread application of endoscopy, barium studies still remain the primary imaging technique in suspected esophageal disorders, especially in cases of dysphagia. Barium studies are simple to perform, inexpensive and highly sensitive. Endoscopy will often be required after a barium swallow, especially for biopsy purposes. It is helpful that barium studies precede endoscopy. This particularly applies to high dysphagia when an unsuspected pharyngeal pouch can be readily entered and perforated with scope. Also esophagoscopy is less good at identifying motility disorders.

**406. Ans: (b) (Hiatal disorders)**

*(Ref. Grainger Diagnostic Radiology 4<sup>th</sup> ed.1011)*

Examination of hiatal area requires the patient to be placed in prone/oblique position on a horizontal table and given a bolus of barium to swallow so there is maximal distension of hiatal segment. When looking for reflux during barium studies, the usual technique is to have the patient in a supine horizontal position and then slowly to lift left side off the couch while screening continuously.

**407. Ans: (b) (Achalasia)**

*(Ref. Grainger's Diagnostic Radiology, 4th ed., 1024)*

Achalasia is a motility disorder of esophagus, probably due to degeneration of myenteric plexus in gastroesophageal junction region, resulting in failure of relaxation of the gastroesophageal junction.

Clinical features include increasing dysphagia, repeated attacks of aspiration pneumonia (when esophagus becomes dilated and fills with food debris).

CXR may reveal absent fundic bubble, areas of aspiration pneumonitis in lung fields and mediastinal air-fluid level. Earliest change seen on Barium study is defective distal peristalsis associated with a slight narrowing at G-E junction. Sometimes marked nonpropulsive contractions in the body of esophagus (vigorous achalasia) may be seen.

The characteristic "bird-beak" appearance of GE junction, best demonstrated in erect position, may also be seen.

With severe achalasia substantial esophageal dilatation (sigmoid esophagus) occurs containing huge food residue and fluid, seen as fluid level at aortic arch.

Apart from pneumatic dilatation of affected segment, Heller's operation is surgical treatment for achalasia.

**408. Ans: (b) (Carcinoma esophagus)**

(Ref. Grainger Diagnostic Radiology, 4th ed., 1025)

**Barium study feature of few esophageal diseases:**

**A. Tertiary esophageal contractions (presbyesophagus, diffuse esophageal spasm, neuromuscular diseases)**

- "Yo-Yo" motion of barium
- "Corkscrew" appearance (scalloped configuration of barium column)
- "Rosary-bead/Shish kebab" configuration (compartmentalization of barium column)

**B. Feline esophagus (transient contraction of longitudinally oriented muscularis mucosa)**

- Normal variant
- Gastroesophageal reflux disease

**C. Double-barrel esophagus**

- Dissecting intramural haematoma
- Mallory-Weiss tear
- Intramural abscess
- Intraluminal diverticulum

**D. Achalasia cardia**

- Megaesophagus/sigmoid esophagus
- "Bird beak" deformity
- Absence of primary peristalsis below level of cricopharynx
- Hurst phenomenon (temporary transit through cardia when hydrostatic pressure of barium column is above toxic LES pressure)
- Vigorous achalasia (numerous tertiary contractions in nondilated distal esophagus of early achalasia)

**E. Scleroderma**

- Esophageal shortening
- Sliding hiatus hernia
- Hidebound esophagus

**409. Ans: (a) (Candidial oesophagitis)**

**Candidial oesophagitis**

- Cobble stone mucosa
- Shaggy/fuzzy contour of the esophagus with small diffuse superficial ulcers
- Plaques
- Thickened mucosal folds

**Cytomegalovirus oesophagitis**

- Giant ovoid flat ulcers (vasculitis of submucosal vessels)
- Gastroesophageal junction with adjacent part of stomach is commonly affected.

**Herpes oesophagitis**

- Discrete superficial punctate/linear serpentine/stellate/diamond shaped ulcers

**Hiatus hernia**

- Epiphrenic bulge
- > 4 longitudinal coarse thick gastric folds above gastroesophageal junction or in the suprahiatal pouch
- Distance between B ring and hiatal margin > 2 cm
- Peristalsis causes above hiatus

**410. Ans: (a) (Carcinoma of Esophagus)**

(Ref. Grainger Diagnostic Radiology, 4th ed., 1025)

**Carcinoma oesophagus is characterized on barium swallow by:**

- Rat-tail esophagus
- Shouldering sign
- Mucosal irregularity

**411. Ans: (c) (Diffuse esophageal spasm)**

(Ref. PL Dhingra ENT 3rd ed. 399; Sutton's Textbook of Radiology, 549)

**Esophageal motility disorders**

- a) Primary - Achalasia  
Diffuse esophageal spasm  
Presbyesophagus  
Nutcracker oesophagus  
Achalasia  
Congenital TO fistulae  
Intestinal pseudoobstruction
- b) Secondary - Connective tissue disorders  
Neuromuscular disease  
Chemical/physical injuries  
Metabolic and endocrine disorders

**Diffuse esophageal spasm:** Compartmentalization of esophagus by numerous tertiary contractions, i.e., episodes of pronounced abnormal motility occurs without cause, causing severe chest pain.

The intermittent nature of the disorders makes it difficult to diagnose by Barium studies; 24 hours. Manometry is required. The tertiary contractions are nonpropulsive, uncoordinated and nonperistaltic and hence seen as intermitted riggles along the wall of esophagus, as multiple simultaneous contraction rings, or as a segmented Barium column producing a 'cork-screw' appearance.

**412. Ans: (d) (Compression of esophagus by aberrant blood vessel)**  
(Ref. Grainger's Diagnostic Radiology 4th ed., 946, 1027)

**Dysphagia lusoria**

- ◆ Dysphagia due to vascular rings is known as dysphagia lusoria.
- ◆ Abnormalities of the great vessels can contract the structures in mediastinum, namely the trachea and esophagus.
- ◆ Many vascular rings can be explained by the persistence of failure to regress of parts of the aortic arch system during embryonic development.
- ◆ Barium swallow, bronchoscopy or angiography are investigations to diagnose but angiography is diagnostic.
- ◆ Impressions and displacement of esophagus from vascular causes may be congenital or acquired. Congenital lesions like aberrant right subclavian artery (0.5%) and right-sided aortic arch with aberrant left subclavian artery may rarely cause esophageal symptoms (dysphagia lusoria) and are often demonstrated as chance findings.
- ◆ The aberrant right subclavian artery arises as the last branch of aortic arch; its first part is persistence part of distal right arch, which may be larger than its expected diameter, known as KOMMERELL'S diverticulum. This aberrant vessel passes obliquely upwards and to right, posterior to esophagus, causing posterior indentation on it. If the vessel is dilated at this point it makes wide indentation. There is no vascular ring with this anomaly and it is almost always asymptomatic.
- ◆ Aberrant left subclavian artery from right aortic arch is the last branch and passes upwards and to left behind esophagus. A vascular ring is usually formed by arterial depth joins the left pulmonary artery to the left subclavian artery, which occasionally may cause significant esophageal compression.
- ◆ Treatment is indicated for the relief of symptoms and is usually directed at dividing the nondominant avascular component of the rings.

**413. Ans: (a) (Abnormal origin of left subclavian artery)**  
(Ref. Grainger's Diagnostic Radiology, 4th ed. 946, 1027 and above Q)

Aberrant left subclavian artery is a common cause of dysphagia lusoria. Aberrant left subclavian artery from right aortic arch is the last branch and passes upwards and to left behind esophagus. A vascular ring is usually formed by arterial depth joins the left pulmonary artery to the left subclavian artery, which occasionally may cause significant esophageal compression.

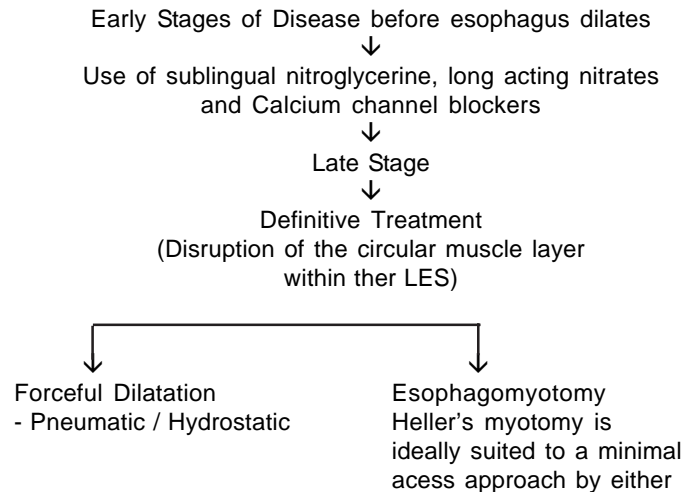
**414. Ans: (d) (Diffuse esophageal spasm)**

(Ref. Harrison 15<sup>th</sup> Edition, Pg.1675; 14<sup>th</sup> Edition, Pg.1592; Bailey and Love 22<sup>nd</sup> Edition, Pg.660)

Diffuse esophageal spasm is synonymous with 'corkscrew esophagus' or Rosary esophagus. In diffuse esophageal spasm, barium swallow shows that normal sequential peristalsis below the aortic arch is replaced by uncoordinated simultaneous contractions that produce the appearance of curling or multiple ripples in the wall, sacculations, and pseudodiverticula the "corkscrew" esophagus.

**415. Ans: (b) (Laparoscopic myotomy)**

Efficacy of botulinum toxin is not yet established and follow up in such patients has been disappointing. Myotomy (Laparoscopic or open surgical) and pneumatic dilatation are the two most widely used and analyzed methods of definitive therapy in achalasia cardia. Treatment of Achalasia Cardia is directed towards relieving the obstruction caused by non-relaxing lower esophageal sphincter.



**Intrasphincteric botulinum toxin injection** into the LES through a flexible esophagoscope is a novel pharmacological treatment. The potent neurotoxin inhibits the release of acetylcholine from nerve endings. However follow up in such patients has been disappointing despite encouraging early results  
(*Ref. Sabiston, Pg. 16,721; Harrison 15<sup>th</sup> Edition, Pg.1645*)

**416. Ans: (a) (Lower oesophagus lined by columnar epithelium)**

Barrett's esophagus is defined as a columnar metaplasia of distal esophagus.

The metaplastic columnar epithelium may be gastric or intestinal in type.

To qualify for the term Barrett's, the metaplastic epithelium either: must extend 3 cm above normal G. E. junction or in shorter segments must have intestinal type metaplasia on biopsy.

**417. Ans: (a) (Barrett's esophagus)**

In Barrett's esophagus there is a metaplastic change in the esophageal mucus membrane. The resulting columnar epithelium is susceptible to the development of the adenocarcinoma. The risk of developing adenocarcinoma in Barrett's esophagus is 50-100 times that of general population. If 100 patients with Barrett's esophagus are followed prospectively for one year, one adenocarcinoma can be expected for that group.

Alcohol abuse, achalasia, and smoking are all risk factors for the development of squamous carcinoma of the esophagus.

**418. Ans: (b) (Middle third)**

(*Ref. Harrison 14<sup>th</sup> Edition, Pg.568, 15<sup>th</sup> Edition, Pg.579*)

Squamous cell Ca and Adenocarcinoma are the commonest types of Carcinoma esophagus:

Squamous cell Ca is the commonest type in India.

Adenocarcinoma is the commonest type in most western countries and is increasing in incidence. Squamous cell Ca is commonest carcinoma that often affects upper 2/3 of the esophagus.

Commonest site of squamous cell carcinoma is the middle 1/3<sup>rd</sup>. Adenocarcinoma is the commonest type of carcinoma that affects the lower 1/3 of esophagus.

This is so because; the carcinoma that arises in Barrett's esophagus is an adenocarcinoma.

Squamous cell Carcinoma

Cervical esophagus is affected in : 15%

Middle 1/3<sup>rd</sup>:45%

Lower 1/3<sup>rd</sup> : 40%

Commonest site of carcinoma esophagus is middle 1/3<sup>rd</sup> of esophagus.

**419. Ans: (d) (Compression by aberrant blood vessels)***(Ref. Bailey and Love, 23<sup>rd</sup> Edition, Pg. 859)*

Several vascular anomalies may produce dysphagia by compression of the esophagus. Classically this is due to an aberrant right subclavian artery (arteria lusoria). However, vascular rings, such as a double aortic arch, more commonly compress the oesophagus. Dysphagia occurs in only a minority of cases and usually presents early in childhood, although it can occur in the later years. Treatment is usually by division of the non-dominant component of the ring.

**420. Ans: (c) (Myotomy with excision of the sac)***(Ref. Bailey and Love, 23<sup>rd</sup> Edition, Pg. 887)*

“The optimum treatment for Zenker’s diverticulum is **excision of the diverticulum combined with cricopharyngeal myotomy** to deal with underlying obstruction.”

In frail patients or those who refuse operation **diverticulo-esophagostomy** is done (ie the septum between the esophagus and the diverticula is divided, by the use of an endoscopic stapler gun known as Dohlman’s procedure).

**Zenker’s diverticulum**

It is a pulsion diverticulum. It lies between the oblique and horizontal fibres of the inferior pharyngeal constrictor.

**421. Ans: (b) (Excision of the diverticulum with cricopharyngomyotomy)***(Ref. Harrison 14th ed. 1595)***Hypopharyngeal (Zenker’s) Diverticulum**

This pulsion diverticulum is situated posteriorly, low in the neck, bulging through the potentially weak area between the oblique and horizontal fibers of the cricopharyngeus muscle.

When small, these diverticula are always posterior, but larger ones tend to flop to one side (usually to the left), and may become so large that esophageal compression or obstruction may result. Stasis is a prominent feature because the neck of the diverticulum is higher than the diverticulum itself, and an air-fluid level is commonly seen on soft-tissue films. Below the diverticulum, the cricopharyngeal sphincter is usually prominent. Many authorities believe that dyskinesia between pharyngeal contraction and cricopharyngeal relaxation plays a major role in pathogenesis.

The approach to treatment is controversial, ranging from diverticulopexy alone (to aid in drainage), to diverticulectomy with no myotomy, to excision of the diverticulum combined with cricopharyngeal myotomy. More correlative studies are in favour of excision of the diverticulum combined with cricopharyngeal myotomy.

**422. Ans: (a) (Stomach)***(Ref. Sabiston Surgery 16<sup>th</sup>/744)*

Generally stomach is preferred over all the other visceral organs as a visceral esophageal substitute, being far more resilient than either jejunum or colon and easily reaching the neck to replace the entire thoracic esophagus. It has a good blood supply. Colonic interposition is a tremendous operative undertaking in a patient with esophageal carcinoma and should be utilized only when stomach is not suitable for esophageal replacement. Colon is used if the patient has undergone a partial or total gastrectomy previously, or if tumor involves the stomach to preclude a 5 cm margin. Jejunal loops can also be used, but limited vascular supply restricts mobility.

**423. Ans: (a) (Achalasia cardia)**

*Ref: (Dhingra ENT-3<sup>rd</sup>/400)*

Presence of dysphagia which is more for liquids than for solids along with a characteristic rat tail appearance on radiography in a young patient suggests the diagnosis of achlasia.

Malignancy (CA esophagus) usually presents with dysphagia which is more for solids than for liquids and is seen in the elderly.

Zenker's diverticulum and esophageal spasm do not show a rat-tail appearance on radiography.

**424. Ans: (a) (Zenker's diverticulum)**

*Ref: (Dhingra-3<sup>rd</sup>/330)*

Regurgitation of food eaten 3 days ago hints to the possibility of another sac / diverticulum which stores food. Age of the patient and gurgling sound support the diagnosis of Zenkers diverticulum.

Zenker's diverticulum

<b>What it is:</b>
It is a pulsion diverticulum where pharyngeal mucosa herniates through the Killian's dehiscence (a weak area between two parts of Inferior constrictor)
<b>Age of presentation</b>
This condition is usually seen after 60 years of age (elderly)
<b>Symptomatology / presentation</b>
Dysphagia: As mouth of the sac is wider than the opening of esophagus, food preferentially enters the sac. When the pouch gets filled with food, it presses on the esophagus and produces dysphagia. Gurgling Sound in produced during swallowing. Cough and Aspiration pneumonia: food eaten over the last few days may regurgitate as it collects in the pouch causing cough and aspiration pneumonia. Malnutrition: Patients is often malnourished due to dysphagia.

**425. Ans: (d) (Common in elderly male):**

*Ref: (Harrison-14<sup>th</sup>/1595; Harrison-15<sup>th</sup>/1648, 579; (Not in Harrison-16<sup>th</sup>) Kumar Clark-5<sup>th</sup>/267; Dhingra-3<sup>d</sup>/399)*

Plummer Vinson syndrome refers to the combination of hypopharyngeal webs and iron deficiency anaemia in middle aged women.

Plummer Vinson Syndrome (Patterson Kelly)
Upper esophageal web Iron deficiency anaemia Koilonychias Glossitis and angular stomatitis

**426. Ans: (d) (Benzene therapy):**

*Ref: (Harrison-15<sup>th</sup>/578; Harrison-16<sup>th</sup>/524)*

1. Alcohol consumption
2. Smoking cigarettes
3. Ingested Carcinogens
Nitrates Smoked opiates Fungal toxins is pickled vegetables
4. Mucosal damage
Chronic Achalasia Lye ingestion/ Hot tea Radiation induced strictures
5. Host Susceptibility
Patterson Kelley syndrome or Plummer Vinson syndrome Esophageal web + Glossitis + Iron deficiency Tylosis palmaris et plantaris : Congenital hyperkeratosis and pitting of palms and soles
6. Chronic Gastric Reflux, ie. Barrett's esophagus for Adenocarcinoma

**427. Ans: (d)(Ca Esophagus):**

*(Ref. Harrison-15<sup>th</sup>/579; Harrison-16<sup>th</sup>/524)*

Congenital hyperkeratosis and pitting of palms and soles (i.e. tylosis palmaris et plantaris) is a known etiological factor for squamous Ca of Esophagus – Harrison.

**428. Ans: (a) (Barrett's Esophagus):**

*Ref: (Schwartz Pre-Test/Q. 434)*

In Barrett's esophagus there is a metaplastic change in the esophageal mucus membrane. The resulting columnar epithelium is susceptible to the development of the adenocarcinoma. The risk

of developing adenocarcinoma in Barrett's esophagus is 50-100 times, that of general population. If 100 patients with Barrett's esophagus are followed prospectively for one year, one adenocarcinoma can be expected in that group. Alcohol abuse, achalasia, lye stricture and smoking are all risk factors for the development of squamous carcinoma of the esophagus.

**429. Ans: (b) (Barrett's esophagus)**

Ref: (Bailey Love-23<sup>rd</sup>/870)

Adenocarcinoma is seen in Barrett's esophagus.

**Barrett's esophagus** is a metaplastic change in the lining mucosa of esophagus in response to chronic gastroesophageal reflux. In Barrett's esophagus the junction between esophageal mucosa (squamous) and gastric mucosa (columnar) moves proximally such that the lower part of esophagus now becomes lined with different types of gastric mucosa. This part of oesophagus has an increased risk for adenocarcinoma i.e. Adenocarcinoma is seen in Barrett's esophagus.

**430. Ans: (b)(Middle third)**

Ref: (Harrison-14<sup>th</sup>/568, 15<sup>th</sup>/579; 16<sup>th</sup>/524)

<p>Cervical esophagus is affected in: 15%  Middle 1/3<sup>rd</sup> esophagus is affected in: 35%  Lower 1/3<sup>rd</sup> esophagus is affected in: 50%</p>
--

Squamous cell Carcinoma and Adenocarcinoma are the commonest types of

Squamous cell carcinoma is the commonest type in India

Adenocarcinoma is the commonest type in most western countries and is increasing in incidence.

Commonest site of carcinoma esophagus is lower one third.

Commonest site of squamous cell carcinoma of esophagus is middle one third.

Common site of adenocarcinoma of esophagus: Lower one third.

Squamous cell CA is the commonest carcinoma that often affects upper 2/3 of the esophagus.

Adenocarcinoma is the commonest type of carcinoma that affects the lower 1/3 of esophagus. This is so because; the carcinoma that arises in Barrett's esophagus is an adenocarcinoma.

**431. Ans: (a) (Cisplatin)**

Ref: (Bailey-23<sup>rd</sup>/879; Bailey-24<sup>th</sup>/1015)

Chemotherapy for esophageal cancer has improved considerably with the advent of Regimens containing Cisplatin – Bailey.

The best responses are seen in Squamous cell carcinomas.

**432. Ans: (a) (Acute tubular necrosis)**

(Ref. KD Tripathi -5<sup>th</sup> ed. 777)

The most important toxicity of cisplatinum is renal impairment.  
Acute tubular necrosis is a manifestation of renal impairment.

**433. OESOPHAGUS:**

1. Average length of oesophagus is 25 cm.
2. It has got four constrictions normally present at following sites:
  - a) 10 cm from the incisor teeth (At the junction of cricopharynx, the narrowest part).
  - b) 15 cm from the incisor teeth (where it is crossed by left bronchus).
  - c) 25 cm from the incisor teeth (where it is indented by left atrium).
  - d) 40 cm from the incisor teeth (at the oesophago-cardiac junction).
3. It is the most muscular segment of GIT
4. Upper one third has striated muscle, lower two third oesophageal wall is composed of inner circular muscle and outer longitudinal muscle without serosal layer.
5. Toughest layer of oesophagus is muscularis mucosa.
6. Only myenteric plexus is present in lower two third of oesophagus while in upper one third, both myenteric and meissner's plexuses are absent.
7. Mucosal lining is squamous except in distal 1–2 cm, which is lined by columnar epithelium.
8. Oesophagus reaches abdomen through a hiatus in right crus of diaphragm at the level of T10.
9. Blood supply of oesophagus:
  - a) Upper one-third—Inferior thyroid artery
  - b) Middle one-third—Oesophageal branches of aorta
  - c) Lower one-third—Branches from left gastric artery.

**434. Ans: (a), (b), (c), (d)**

Following factors guard against reflux of gastric contents in to the oesophagus:  
Sphincteric action of lower oesophageal muscle fibers or fibers of right crura.  
Mucosal flap produced by muscularis mucosa of the stomach.  
Difference between intrathoracic and intraabdominal pressure.  
Acute gastroesophageal angle.

**435. Ans: (a) (Oesophagitis)**

(Ref. Robbin's pathology-7<sup>th</sup> Ed<sup>n</sup>-802)

- ◆ **Hiatal hernia** is characterized by separation of diaphragmatic crura and widening of the space between the muscular crura and esophageal wall.

- ◆ Types:
  - a) Sliding or axial hernia (95%)
  - b) Paraesophageal or nonaxial hernia (5%)
- ◆ Complications of hiatal hernia are numerous, but reflux esophagitis is frequent with sliding hernias and loss of tone of LES with regurgitation of peptic juices into esophagus is probably the result of rather than the cause of a sliding hernia.
- ◆ Other complications include:
  - ◆ Aspiration pneumonitis
  - ◆ Oesophageal perforation
  - ◆ Carcinoma oesophagus
  - ◆ Ulcerations and bleeding of esophagus
  - ◆ Strangulation/obstruction

**436. Ans: None**

The nasopharynx (epipharynx) extends from the base of the skull to the tip of the soft palate (uvula) and is concerned only with respiration. The oropharynx (meso) extends from the pharyngeal surface of the soft palate to the hyoid bone, and the hypopharynx (laryngo-) from the hyoid bone to the pharyngoesophageal segment; it includes the cricopharyngeus muscle. From above downward hypopharynx, consist of epiglottis, valleculae, pharyngeal walls, and pyriform sinuses.